

# Comparative evaluation of the efficacy of chitosan and formocresol as medicaments for pulpotomy in primary molars: A clinical pilot study

 Nihal R Kothari<sup>1</sup> ,  S K Srinath<sup>2</sup>,  Sulakshana S<sup>3</sup>,  Aswathy T<sup>4</sup>,  Padmapriya S<sup>5</sup>

## Highlights

This study evaluated the efficacy of chitosan which is a non toxic, bioactive material with anti microbial and wound healing properties as pulpotomy medicaments in primary teeth.

While both groups showed similar success rate clinically, chitosan had better success rate radiographically.

Chitosan is a safe, biocompatible and effective medicament for pulpotomy in primary molars. Owing to its advantages of chitosan, it can be used as an alternative to formocresol as a pulpotomy agent.

## Abstract

**Aim:** To compare the clinical and radiographic effectiveness of chitosan and formocresol as pulpotomy medicaments in primary molars. **Methods:** Children of age 4-8 years old, who were physically and mentally healthy without any known medical history of systemic conditions contraindicating pulp therapy with at least one deep carious primary molars indicated for pulpotomy, were recruited. Pulpotomies were performed on 64 teeth divided into 2 groups, Group A (chitosan) and Group B (formocresol), followed by stainless steel crowns. Evaluation of clinical and radiological success was done at 1, 3 and 6 months follow up. Chi Square Test was used to compare the clinical and radiological parameters between study groups at different time intervals ( $p < 0.05$ ) **Results:** Clinical success rate in both groups was 96.6% and radiographic success rate in chitosan was 96.6%, but formocresol was 89.6%. **Conclusions:** Chitosan was found to be an effective medicament for pulpotomy in primary molars. While chitosan also showed improved success rate compared to formocresol, it was not statistically significant.

**Keywords:** Chitosan; Formocresol; Pulpotomy

<sup>1</sup> Post graduate, Department of Pedodontics, Government Dental College And Research Institute, Bengaluru-560002

<sup>2</sup> Professor and Head, Department of Pedodontics, Government Dental College And Research Institute, Bengaluru-560002

<sup>3</sup> Assistant Professor, Department of Pedodontics, Government Dental College And Research Institute, Bengaluru-560002

<sup>4</sup> Post graduate, Department of Pedodontics, Government Dental College And Research Institute, Bengaluru-560002

<sup>5</sup> Post graduate, Department of Pedodontics, Government Dental College And Research Institute, Bengaluru-560002

## Correspondence:

Department of Pedodontics,  
Government Dental College And  
Research Institute, Bengaluru-  
560002

E-mail address:

[nihalkothari44@gmail.com](mailto:nihalkothari44@gmail.com)

**Received:** 02 May 2021

**Accepted:** 28 June 2021

**Online First:** 01 July 2021

## INTRODUCTION

The primary objective of vital pulp therapy in deciduous teeth are treating reversible pulpal injuries and maintaining pulp vitality/function.<sup>1</sup> American Academy of Pediatric Dentistry recommends that the teeth diagnosed with a normal pulp requiring pulp therapy or with reversible pulpitis should be treated with vital pulp procedures.<sup>2</sup> A recent review revealed<sup>3</sup> that pulp inflammation in primary molars precedes its exposure. It has also reported the pulp pathology with the extent of the carious lesion and found that most primary molars with large carious lesions manifest pulp inflammation involving the entire pulp horn, but rarely the root canal tissue. This would mean that in most primary teeth with large caries, which are indicated for a pulpotomy, the removal of the coronal pulp alone would render them free of inflammation.<sup>3</sup>

Pulpotomy is described as complete removal of coronal portion of the dental pulp, the remaining radicular tissue is judged to be vital without suppuration, purulence, necrosis, or excessive hemorrhage that cannot be controlled by a damp cotton pellet after several minutes followed by the placement of suitable dressing or medicament that will promote healing and preserve vitality of the tooth.<sup>4</sup>

Formocresol has been considered the gold standard pulpotomy medicament for the past 60 years.<sup>6</sup> This material is widely accepted by dentists, owing to its ease of application, fixative ability, and bactericidal action.<sup>7</sup> However, its adverse effects are well-known, including potential carcinogenicity, mutagenicity, and cytotoxicity.<sup>8</sup> Pashley and Myers reported that formaldehyde is absorbed systemically from pulpotomy sites and is distributed to distant sites.<sup>9</sup>

In this awakening, the search for ideal pulpotomy agent is commenced. Various medicaments and techniques have been studied in primary molar pulpotomy. Yet an ideal pulpotomy agent has not yet been established. Chitosan is a biodegradable polysaccharide which

is obtained by alkaline de-acetylation of chitin. It is non-toxic, biocompatible, bioadhesive, biodegradable, has wound healing traits and possesses antimicrobial activity.<sup>10</sup> Chitosan has emerged as a potential material for bio-dental applications. The chitosan based materials have been explored extensively for a wide range of dental applications like cariostatic, guided tissue regeneration, adhesion and dentine bonding, enamel repair and remineralisation. Chitosan has also been investigated for regeneration of dentine-pulp complex.<sup>11,12,13</sup> Chitosan is an effective hemostatic agent. It works by entering into a direct interaction with red blood cells and thrombocytes to form a cross-linked clot barrier.<sup>14</sup> In fact, chitosan can speed the rate of wound healing by enhancing the release of the platelet derived growth factor-AB (PDGF-AB) and the transforming growth factor- $\beta$ 1 (TGF- $\beta$ 1).<sup>15</sup> Hydrogels containing chitosan have shown to promote the odontogenic differentiation of Dental Pulp stem cells (DPSCs).<sup>16</sup> Thus owing to these benefits of chitosan it was chosen as medicament for pulpotomy.

Hence, the purpose of this in-vivo pilot study was to evaluate clinically and radiographically the efficacy of chitosan and formocresol as pulpotomy medicaments in primary molars. The null hypothesis was that there would be no difference between both groups in the pulpotomy of primary teeth.

## METHODS

This concurrent parallel randomized controlled clinical study was conducted in Department of Pediatric Dentistry, Government Dental College and Research Institute Bengaluru. The study was adhered to the Consolidated Standards of Reporting Trials (CONSORT) guidelines. Ethical approval was obtained by the institutional ethical committee via GDCRI/IEC-ACM(2)/9/2018-2019 9/11/2018. Informed consent was taken from parents and/or guardians.

## Sample size estimation

A power analysis was established by G\*power, version 3.0.1 (Franz Faul Universitat, Kiel, Germany). A sample size of 58 subjects, which was rounded off to 64 (32 in each group considering 10% dropout), would yield 80% power to detect significant differences, with effect size of 0.5 and significance level at 0.05.

## Inclusion and exclusion criteria

Children of age 4-8 years old, who were physically and mentally healthy without any known medical history of systemic conditions contraindicating pulp therapy with at least one deep carious primary molars indicated for pulpotomy, were recruited. The included children had “positive” or “definitely positive” behavioral ratings according to the Frankl behavior classification scale. Each parent signed informed consent for the child’s participation in the study. No child was excluded based on gender, race, social status, or economic status. The primary molars with restorable crown having extensive caries which resulted in a

carious, or mechanical pulp exposure but no evidence of radicular pathology, abscess, root resorption, spontaneous pain and tender on percussion, were included in the study. Included teeth had vital pulp with healthy periodontium and possess at least 2/3rd of its root length. After amputation of the coronal pulp, hemorrhage was easily controllable. Any instance with uncontrolled bleeding from the amputation site, the tooth was excluded from the study.

A CONSORT diagram showing the flow of the study design is presented in Figure 1. 51 eligible children were screened for the study out of which, 47 met the inclusion criteria. Exclusion of children was based on consent, signs and symptoms of irreversible pulpitis. Among the 47 children, 64 teeth were randomly allocated to either chitosan group (Group A) or formocresol group (Group B) with 32 teeth in each group. To eliminate selection bias, randomization was performed by lottery method so that every tooth gets an equal chance of being allocated into either group.

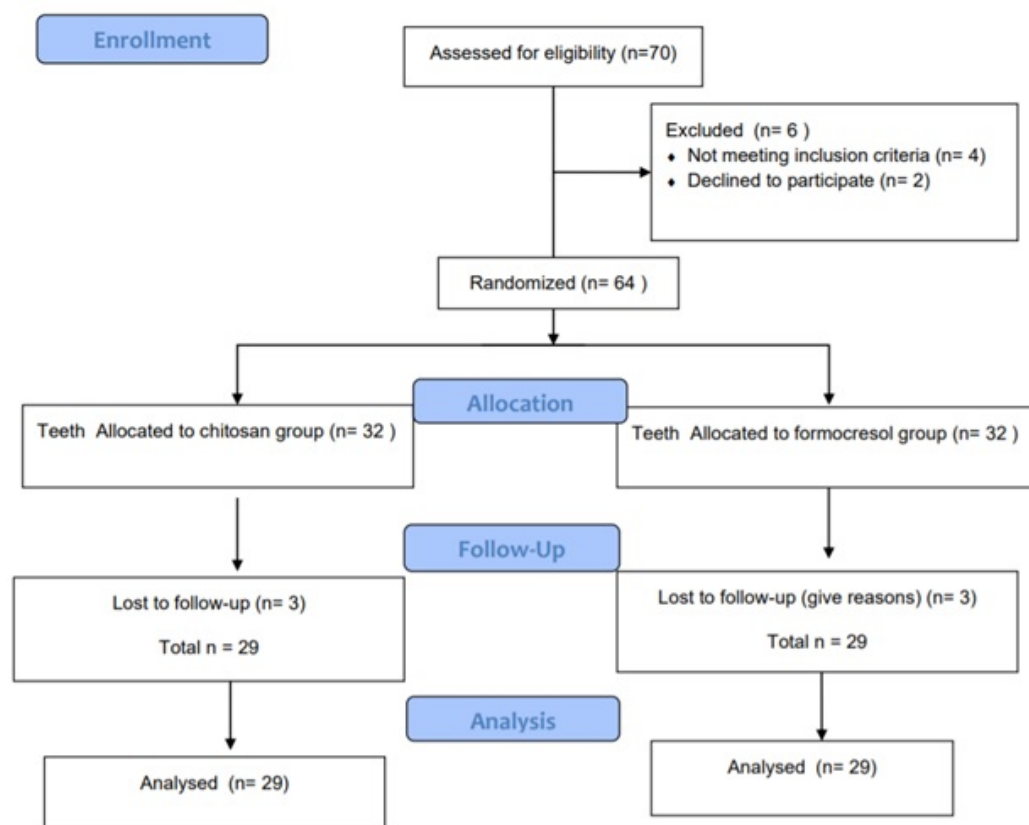


Figure 1. CONSORT diagram showing the study design and follow-up

Single operator (NK) performed all the procedures. Conventional pulpotomy procedures were performed on all teeth. After application of topical anesthesia, teeth were anesthetized using 2% lignocaine in 1:1,00,000 epinephrine (Regain Laboratories, Hisar, India) (Figure 2a). The entire procedure was carried under rubber dam isolation (Figure 2b). A sterile round bur was used to remove all carious dentin and access to the pulp chamber was gained (Figure 2c). Coronal Pulp was removed using sharp spoon excavator and amputated till the canal orifice. The pulp chamber was cleaned properly with normal saline, followed by haemostasis which was achieved by placing sterile wet cotton pellets for 5 minutes (Figure 2d,e). After the standardized technique, the pulp stumps of the teeth of the patients assigned for group A were covered with a cotton pellet dipped in chitosan solution for 5 minutes and the pulp

stumps of the teeth of the patients assigned for group B were covered with cotton pellet dipped and squeezed in Buckley's formocresol, for 5 minutes (Figure 2f). Then the wound surface of the pulp in both groups were covered with a thick mix of zinc-oxide eugenol cement (Figure 2g) and teeth were restored with glass ionomer cement (Figure 2h). All treated teeth received preformed primary stainless steel crowns (3M ESPE, Seefeld, Germany) (Figure 2i). Finally, a postoperative periapical radiograph was taken for each tooth to confirm proper dressing of the remaining pulp tissues. Parents and children were given routine oral hygiene instructions and all possible outcomes were explained to them and they were asked to report any pain, discomfort, swelling, or pus discharge immediately. The children were recalled for clinical and radiographic examination postoperatively at 1, 3 and 6 months (Figure 3).

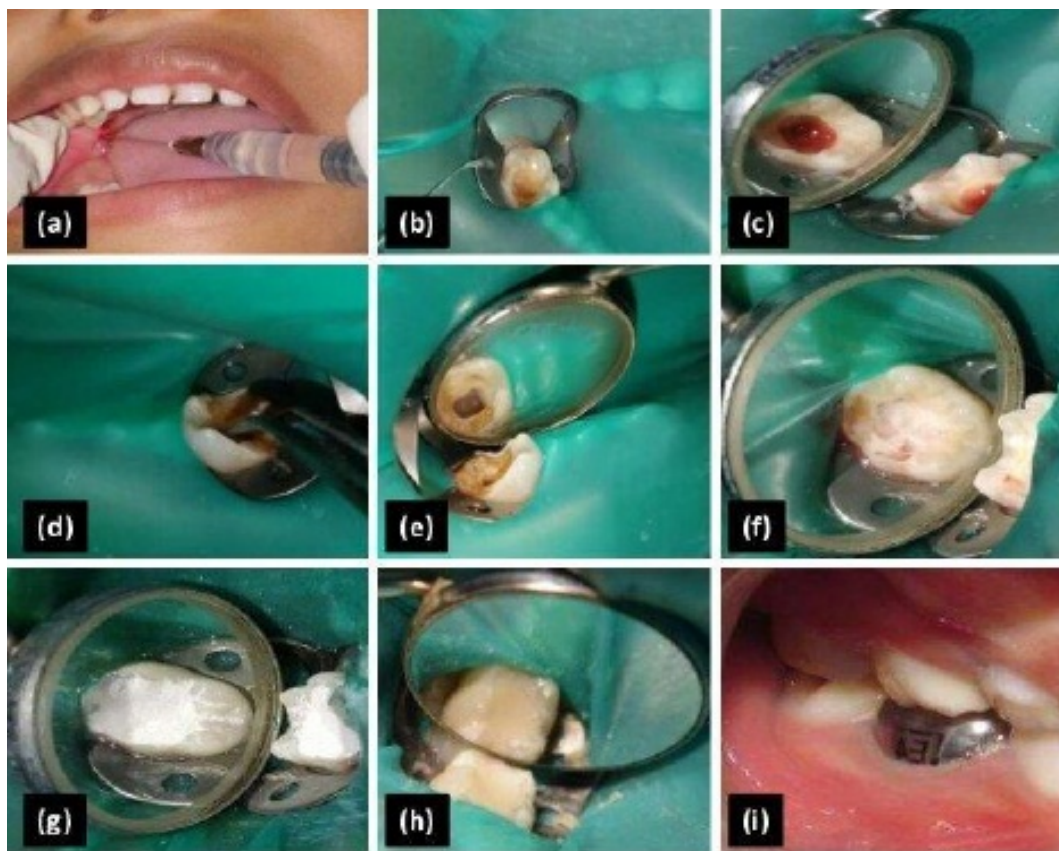

Figure 2. Followed clinical procedure in pulpotomy. A: Administration of local anesthesia; B: Isolation with rubber dam; C: Access to the pulp chamber and notice the bright red bleeding; D and E: Application of pressure to control bleeding; F: Application of medicament. G,H and I: Zinc oxide eugenol base followed by glass ionomer cement restoration and placement of stainless steel crown



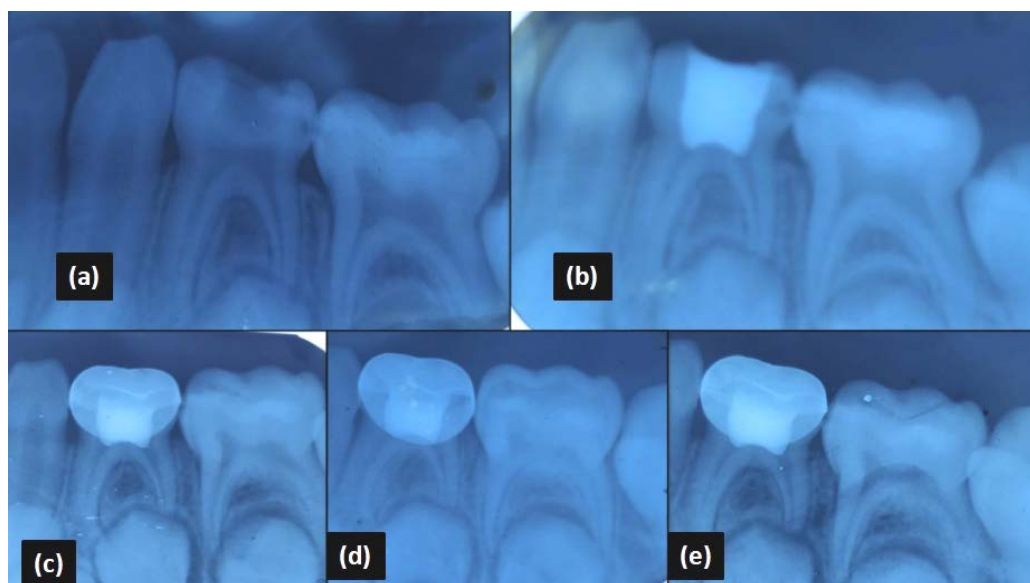


Figure 3. Representative primary first mandibular teeth with initial and follow-up radiographs. A: Pre operative; B: Post operative; C: Follow up radiograph at 1 month; D: Follow up radiograph at 3 month; E: Follow up radiograph at 6 month

In order to eliminate observer bias, two blinded and calibrated evaluators assessed the participants clinically and radio-graphically. Parents, child and the evaluators were blinded.

Clinical success was considered as the absence of any adverse clinical signs or symptoms, such as pain, tenderness on percussion, abscess, sinus opening and, pathologic mobility. Radiographic success was considered as absence of periradicular radiolucency, furcation involvement, widening of periodontal ligament space, and pathologic internal/external root resorption.

### Statistical analysis

SPSS (Statistical Package for Social Sciences, V22.0. Armonk, NY: IBM Corp) was used to perform statistical analyses. Chi Square test was used to compare the clinical and radiological parameters between study groups at different time intervals. The level of significance was set at  $p < 0.05$ .

### RESULTS

Sixty four primary molars in patients of age group 4-8 years were randomly and equally allocated either chitosan (Group A) or formocresol (Group B) groups. In Group A (10 females, 22 males) and in group B (12 females and 20 males) with a median age of 6 years (range=4-8 years) were included. Table 1 shows age ( $p = 0.36$ ) and gender ( $p = 0.60$ ) distribution between study groups. Out of sixty four teeth, 6 teeth could not be followed up and hence were excluded from the study. Fifty eight teeth were available for follow up at 6 months and the teeth were distributed in the following manner: In Group A (3 – maxillary first molars, 12- mandibular first molars, 2- maxillary second molars, 12- mandibular second molars) and in Group B (3- maxillary first molars, 11- mandibular first molars, 3 maxillary second molars, 12 mandibular first molars).

All 58 teeth were followed up at 1 month, 3 months and 6 months time intervals. The teeth were evaluated on basis of clinical signs, symptoms and radiographical findings.

Table 1. Comparison of age and gender distribution between study groups

Variable	Category	Group A		Group B		$\chi^2$ value	P value
		<i>n</i>	%	<i>n</i>	%		
Age	4 years	3	9.4%	3	9.4%	4.376	0.36
	5 years	8	25.0%	3	9.4%		
	6 years	8	25.0%	14	43.8%		
	7 years	6	18.8%	4	12.5%		
	8 years	7	21.9%	8	25.0%		
Sex	Males	22	68.8%	20	62.5%	0.277	0.60
	Females	10	31.3%	12	37.5%		

In both groups the clinical success rate and radiographical success rate was 100% at 1 month interval. At 3 months interval one tooth in Chitosan Group had spontaneous pain and tenderness with internal resorption noted radiographically. In formocresol group one tooth had spontaneous pain, tenderness on percussion, abscess and internal resorption. Both teeth were then extracted. Clinical and radiographic success rate for both groups at 3 months was 96.6% and there was no statistically significant difference. At 6 months interval clinical success rate for both

groups is 100%. Radiographically one tooth in formocresol group had furcal radiolucency and external resorption; another tooth had internal resorption; while clinically both teeth were asymptomatic. It was then decided to monitor the child for any other signs. The radiographic success rate at 6 months in formocresol group was 92.8% and 100% in chitosan group (Table 2). At 6 months interval one tooth in group B had furcal radiolucency and external resorption; another tooth had internal resorption (Figure 4b,c).

Table 2. Comparison of Success Rate at 1, 3 and 6 months between study groups

Success Rate			Group A		Group B		$\chi^2$ value	P value
			<i>n</i>	%	<i>n</i>	%		
1 Month	Clinical	Success	32	100%	32	100%	---	---
		Failure	0	0.00%	0	0.00%		
	Radiographical	Success	32	100%	32	100%		
		Failure	0	0.00%	0	0.00%		
3 Months	Clinical	Success	28	96.60%	28	96.60%	1.018	0.31
		Failure	1	3.40%	1	3.40%		
	Radiographical	Success	28	96.60%	28	96.60%		
		Failure	1	3.40%	1	3.40%		
6 Months	Clinical	Success	28	100%	28	100%	---	---
		Failure	0	0.00%	0	0.00%		
	Radiographical	Success	28	100%	26	92.80%		
		Failure	0	0.00%	2	7.20%		

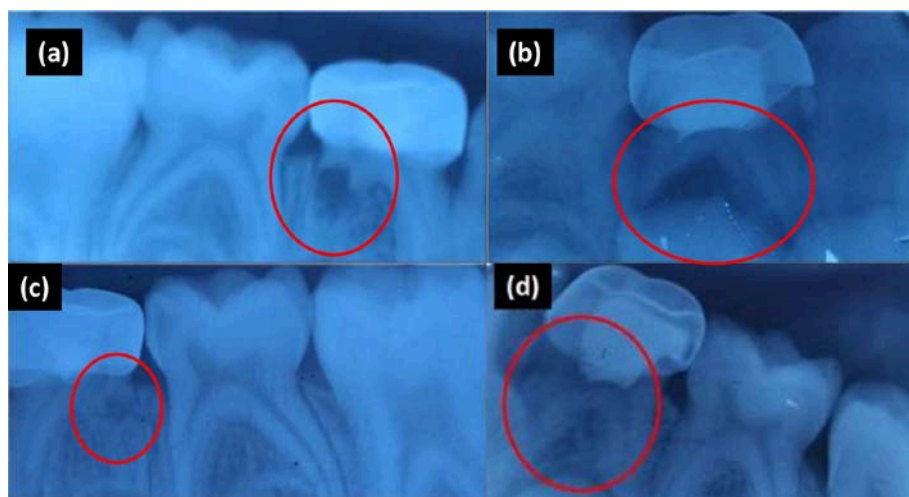


Figure 4. Representative radiographic failures. A: Internal resorption in formocresol group at 3 months; B: Furcal radiolucency and external resorption in formocresol group at 6 months; C: Internal resorption in formocresol group at 6 months; D: Internal resorption in chitosan group at 3 months

By the end of 6 months, the overall clinical success rate in both the groups was 96.6%. Overall radiographic success rate in chitosan

group was 96.6% and in formocresol group was 89.6%. The difference however was not statistically significant (Table 3).

Table 3. Comparison of all clinical and radiographic success rate between study groups

Success Rate		Group A		Group B		$\chi^2$ Value	P-Value
		n	%	n	%		
Clinical	Success	28	96.60%	28	96.60%	0	1
	Failure	1	3.40%	1	3.40%		
Radiographic	Success	28	96.60%	26	89.61%	1.074	0.3
	Failure	1	3.40%	3	10.34%		

## DISCUSSION

The rationale for pulpotomy procedure is based on the healing ability of the radicular pulp tissue following surgical amputation of the affected or infected coronal pulp.<sup>17</sup> The success of vital pulp treatment is largely dependent on an accurate assessment of pulp status.<sup>18</sup> Research has shown that only with histological analysis can the pathological status of the pulp be precisely evaluated.<sup>19</sup> Clinical evaluation is only able to give an indication of the probable state of the pulp.<sup>20</sup> In cases where no radiographic evidence exists for bony degeneration and no inflammatory reaction of radicular pulp tissue is present, the treatment of choice is a vital pulpotomy procedure.<sup>20</sup> Hence,

in this study, judgement of pulp status was done by correlating clinical signs and symptoms, radiographic findings and control of hemorrhage from the site of amputation.

Over the years the pulpotomy procedure has been evolving with newer materials being introduced. Formocresol has been used since decades for deciduous teeth pulpotomy. Formocresol is both a bactericidal and devitalizing agent. With formocresol as the pulpotomy medicament, coagulation necrosis of the tissue occurs at the amputation site. Apical to this is a zone of chronic inflammation, which blends into normal tissue.<sup>21</sup> A high rate of clinical success has been reported for pulpotomies performed on

deciduous teeth with the use of formocresol. Histologic evaluation of the pulp after pulpotomies with use of formocresol shows apparent fixation of portions of the pulp tissue to areas of inflammation and necrosis.<sup>22</sup> Over the years, formocresol has been labeled as being mutagenic, toxic, and carcinogenic.<sup>23</sup> Formocresol as a pulpotomy medicament is becoming less popular. An alternative to the use of this medicament, which does not elicit the same systemic and local problems, would be desirable.

Chitosan is obtained from the deacetylation of chitin, a natural polysaccharide derived from crustacean's exoskeleton. Chitosan is a natural nontoxic, biocompatible, biodegradable polysaccharide with tested antibacterial properties.<sup>24</sup> Chitosan has a range of favourable properties such as anti-bacterial, anti-inflammatory and can be combined with various bioactive materials for osteoconductivity.<sup>25</sup> Chitosan has shown formation of reparative dentin, and has therefore been reported to be an appropriate material for pulpotomy.<sup>26</sup> In vitro study by Yang et al.<sup>27</sup> reported formation of a dentine-pulp complex with use of collagen-chitosan complex in culture of dental pulp stem cells. Animal studies have also showed efficiency in pulp capping compared to calcium hydroxide.<sup>28,29</sup>

Considering the benefits of chitosan, it was chosen as the medicament for pulpotomy in primary molars in our study. The present study was conducted to evaluate the efficacy of chitosan as medicament for pulpotomy in primary molars and was compared with a gold standard pulpotomy medicament, formocresol.

The present study was conducted over 64 teeth and to prevent selection bias the teeth were randomly allocated in both groups ensuring that each patient had equal chance of receiving one of the two pulpotomy medicaments. The procedure in all the selected teeth was performed with rubber dam isolation. Initial hemorrhage control was done by placing sterile cotton pellets on the

radicular pulp stumps under slight pressure for 5 minutes to ensure that the pulp was healthy. The 5-minute mark was chosen because this is the midpoint of the normal bleeding time range (1-9½ minutes).<sup>30</sup> Teeth with insufficient hemostasis were excluded from the study. To restore tooth anatomy, function and to protect remaining tooth structure and provide a biological seal to prevent bacterial infiltration of the remaining vital pulp tissue, stainless steel crown was cemented after the procedure. Farooq<sup>28</sup> and Guelmann<sup>29</sup> have shown that the final restoration of pulpotomized tooth is significantly associated with the success of the pulpotomy.<sup>31,32</sup>

In the present study, a single operator performed the procedure. Two blinded evaluators assessed the clinical and radiographic findings at 1, 3 and 6 months. In the present study, all the clinical parameters and radiographic parameters showed 100% success in both chitosan and formocresol group at 1 month. At 3 months interval one tooth in both groups had pain, tenderness with internal resorption. Clinical and radiographic success rate for both groups at 3 months was 96.6%.

By the end of 6 months overall clinical success rate for both groups was 96.6% and radiographic success rate in chitosan group was 96.6% and in formocresol group was 89.6%. But, there was no statistically significant difference in overall success between the two groups at 1, 3 and 6 months. The results obtained in the present study were in accordance with a previous study<sup>33</sup> which reported a success of 94.44% in chitosan group and 83.33% in formocresol group at the end of 6 months follow up. A recent study<sup>34</sup> also showed clinical success rate of FC pulpotomy as 90.4%. Results of this study were similar to a previous study<sup>35</sup> which reported a success rate of 94.4% in chitosan group with follow-up of 12 months.

The failure of pulpotomy treatment in primary molars could be attributed to the number of factors, one of which may be clinical errors in diagnosis and selection of the case. Another



possible explanation could be the zinc oxide eugenol which was used as sub-base and could be an irritant to pulp cells. The promising clinical and radiographic outcome of vital pulpotomy performed with chitosan may be explained on the bases that chitosan possess antimicrobial properties, biocompatibility, and has no toxic effect.<sup>36</sup> Chitosan is also an excellent hemostatic agent and also increases the formation of reparative dentin and the formation of hard tissues in-vitro.<sup>37</sup>

This study has several limitations. The main limitation of the study was short term follow up of 6 months. Since it was a pilot study a small sample size of 64 was taken. Histological evaluation of the teeth was not done. Therefore, more long term clinical and histological studies and larger study groups are required.. More long term follow up studies with larger sample size and histological evaluation should be conducted.

## CONCLUSIONS

This study concludes that chitosan is an effective medicament for pulpotomy in primary molars. In terms of clinical efficacy both the medicaments showed no difference. Radiographically, chitosan showed improved success rate compared to formocresol. However, findings were not statistically significant. Chitosan was found to be biocompatible medicament. Owing to the shortcomings and health hazards related to formocresol, chitosan can be used as a pulpotomy medicament in primary molars. It is certain that more randomized clinical trials with larger sample size and longer duration of follow up is necessary. Histological studies are also required to confirm the role of chitosan as a pulpotomy medicament.

## REFERENCES

1. Parisay I, Ghoddusi J, Forghani M. A review on vital pulp therapy in primary teeth. *Iran Endod J* 2015;10:6-15
2. AAPD Reference Manual. Pulp therapy for primary and immature permanent teeth. *Pediatr Dent* 2020;21;384-392
3. Duggal MS, Nooh A, High A. Response of the primary pulp to inflammation: a review of the Leeds studies and challenges for the future. *Eur J Paediatr Dent* 2002; 3:111-114
4. Camp JH, Fuks AB. Pediatric endodontics. In: Hargreaves KM, Berman LH, editors. *Cohen's Pathways of the pulp*. 10th ed. USA: Elsevier; 2011.p. 808-857
5. Fuks AB. Current concepts in vital primary pulp therapy. *Eur J Paediatr Dent* 2002;3:115–120
6. Coll JA, Seale NS, Vargas K, Marghalani AA, Al Shamali S, Graham L. Primary tooth vital pulp therapy: A systematic review and meta-analysis. *Pediatr Dent* 2017;39:116-123
7. Sushynski JM, Zealand CM, Botero TM, Boynton JR, Majewski RF, Shelburne CE et al. Comparison of gray mineral trioxide aggregate and diluted formocresol in pulpotomized primary molars: a 6- to 24-month observation. *Pediatr Dent* 2012;34:120-128
8. Hugar SM, Kukreja P, Hugar SS, Gokhale N, Assudani H. Comparative evaluation of clinical and radiographic success of formocresol, propolis, turmeric gel, and calcium hydroxide on pulpotomized primary molars: A preliminary study. *Int J Clin Pediatr Dent* 2017;10:18-23
9. Pashley EL, Myers DR, Pashley DH, Whitford GM. Systemic distribution of <sup>14</sup>C-formaldehyde from formocresol-treated pulpotomy sites. *J Dent Res* 1980;59:602-608.
10. Balata GF, Abdelhady MIS, Mahmoud GM, Matar MA, Abd El-Latif AN. Formulation of Saudi Propolis into Biodegradable Chitosan Chips for Vital Pulpotomy. *Curr Drug Deliv* 2018;15:97-109
11. Kumirska J, Weinhold MX, Thöming J, Stepnowski P. Biomedical activity of chitin/chitosan based materials—influence of physicochemical properties apart from molecular weight and degree of N-acetylation. *Polymers* 2011; 3:1875-1901
12. Rinaudo M. Chitin and chitosan: properties and applications. *J Prog Polym Sci* 2006; 31:603-632
13. Soares DG, Rosseto HL, Basso FG, Scheffel DS, Hebling J, Costa CA. Chitosan-collagen biomembrane embedded with calcium-aluminate

enhances dentinogenic potential of pulp cells. *Braz Oral Res* 2016;30:1-10

14. Radwan-Pragłowska J, Piątkowski M, Deineka V, Janus Ł, Korniienko V, Husak E, et al. Chitosan-based bioactive hemostatic agents with antibacterial properties-synthesis and characterization. *Molecules* 2019;2624:2629

15. Okamoto Y, Yano R, Miyatake K, Tomohiro I, Shigemasa Y, Minami S. Effects of chitin and chitosan on blood coagulation. *Carbohydrate Polymers* 2003;15:337-342

16. Wu S, Zhou Y, Yu Y, Zhou X, Du W, Wan M, et al. Evaluation of Chitosan Hydrogel for Sustained Delivery of VEGF for Odontogenic Differentiation of Dental Pulp Stem Cells. *Stem Cells Int* 2019;19:1-14

17. Fuks AB, Eidelman E. Pulp therapy in the primary dentition. *Curr Opin Dent* 1991;1:556-563

18. Kassa D, Day P, High A, Duggal M. Histological comparison of pulpal inflammation in primary teeth with occlusal or proximal caries. *Int J Paediatr Dent* 2009;19:26-33

19. Schroder U. Agreement between clinical and histologic findings in chronic coronal pulpitis in primary teeth. *Scand J Dent Res* 1977;85:583-587

20. Dummer PM, Hicks R, Huws D. Clinical signs and symptoms in pulp disease. *Int Endod J* 1980;13:27-35

21. Hicks MJ, Barr ES, Flaitz CM. Formocresol pulpotomies in primary molars: a radiographic study in a pediatric dentistry practice. *J Pedod* 1986;10:331-339

22. Chandrashekhar S, Shashidhar J. Formocresol, still a controversial material for pulpotomy: A critical literature review. *J Restor Dent* 2014;2:114-124

23. Myers DR, Shoaf HK, Dirksen TR, Pashley DH, Whitford GM, Reynolds KE. Distribution of <sup>14</sup>C-formaldehyde after pulpotomy with formocresol. *J Am Dent Assoc* 1978;96:805-813

24. Erpaçal B, Adıgüzel Ö, Cangül S, Acartürk M. A General Overview of Chitosan and its Use in Dentistry. *Int Biol Biomed J.* 2019;5:1-11

25. Venkatesan J, Kim SK. Chitosan composites for bone tissue engineering--an overview. *Mar Drugs* 2010;8:2252-2266

26. Imani Z, Imani Z, Basir L, Shayeste M, Abbasi Montazeri E, Rakhshan V. Antibacterial Effects of Chitosan, Formocresol and CMCP as

pulpectomy on *Enterococcus faecalis*, *Staphylococcus aureus* and *Streptococcus mutans*. *Iran Endod J* 2018;13:342-350

27. Yang X, Han G, Pang X, Fan M. Chitosan/collagen scaffold containing bone morphogenetic protein-7 DNA supports dental pulp stem cell differentiation in vitro and in vivo. *J Biomed Mater Res* 2011;108:2519-2526

28. Farea M, Husein A, Halim AS, Abdullah NA, Mokhtar KI, Lim CK, Berahim Z, Mokhtar K. Synergistic effects of chitosan scaffold and TGFβ1 on the proliferation and osteogenic differentiation of dental pulp stem cells derived from human exfoliated deciduous teeth. *Arch Oral Biol* 2014;59:1400-1411

29. Li F, Liu X, Zhao S, Wu H, Xu HH. Porous chitosan bilayer membrane containing TGF-β1 loaded microspheres for pulp capping and reparative dentin formation in a dog model. *Dent Mater* 2014;30:172-181

30. Vargas KG, Packham B, Lowman D. Preliminary evaluation of sodium hypochlorite for pulpotomies in primary molars. *Pediatr Dent* 2006;28:511-517

31. Farooq NS, Coll JA, Kuwabara A, Shelton P. Success rates of formocresol pulpotomy and indirect pulp therapy in the treatment of deep dentinal caries in primary teeth. *Pediatr Dent* 2000;22:278-286

32. Guelmann M, Fair J, Bimstein E. Permanent vs temporary restorations after emergency pulpotomies in primary molars. *Pediatr Dent* 2005;27:478-481

33. Alhamshary A I, El-Bayoumy S Y. Clinical and radiographic evaluation of chitosan-zinc oxide eugenol mix in pulp capping of primary teeth. *AJDSM.* 2020;23:263-270

34. Jayam C, Mitra M, Mishra J, Bhattacharya B, Jana B. Evaluation and comparison of white mineral trioxide aggregate and formocresol medicaments in primary tooth pulpotomy: Clinical and radiographic study. *J Indian Soc Pedod Prev Dent* 2014;32:13-18

35. Shang Jia jian. Clinical study of chitosan on vital pulpotomy to deciduous teeth. *Beijing J of stomatology.* 2003;2:104-106

36. Pogorielov MV, Sikora VZ. Chitosan as a hemostatic agent: current state. *Eur J Med* 2015;1:24-33

37. Renard E, Amiaud J, Delbos L, Charrier C, Montembault A, Ducret M. et al. Dental pulp inflammatory/immune response to a chitosan-enriched fibrin hydrogel in the pulpotomised rat incisor. *Eur Cell Mater* 2020;40:74-87

#### **How to cite this article:**

Nihal R Kothari, S K Srinath, Sulakshana S, Aswathy T, Padmapriya S. Comparative evaluation of the efficacy of chitosan and formocresol as medicaments for pulpotomy in primary molars: A clinical pilot study. *Contemp Pediatr Dent* 2021;2(2):90-100.

#### **Declarations**

**Acknowledgements:** *This research was conducted in Government dental college and research institute, Bangalore, India. The author thanks the Dean of the institute for all support. We also thank Dr. Santhosh for assisting with statistical analysis.*

**Conflict of Interest Statement:** *The authors, certify that they have no commercial associations that might pose a conflict of interest in connection with the submitted article.*

**Ethics Statement:** *Ethical approval was obtained by the institutional ethical committee via GDCRI/IEC-ACM(2)/9/2018-2019 9/11/2018.*

**Informed Consent:** *Informed consent was taken from parents and/or guardians.*

**Author contributions:** *Conception and design: All Authors; Acquisition of data: NRK, AT, PS; Interpretation of data: AT, PS; Drafting article: SKS, SS; Revision article: SKS, SS; Final approval: All Authors*

**Funding:** *This work is not financed.*

**Data Availability:** *The data used to support the findings of this study can be made available upon request to the corresponding author.*

**Peer-review:** *Externally double-blinded peer-reviewed.*